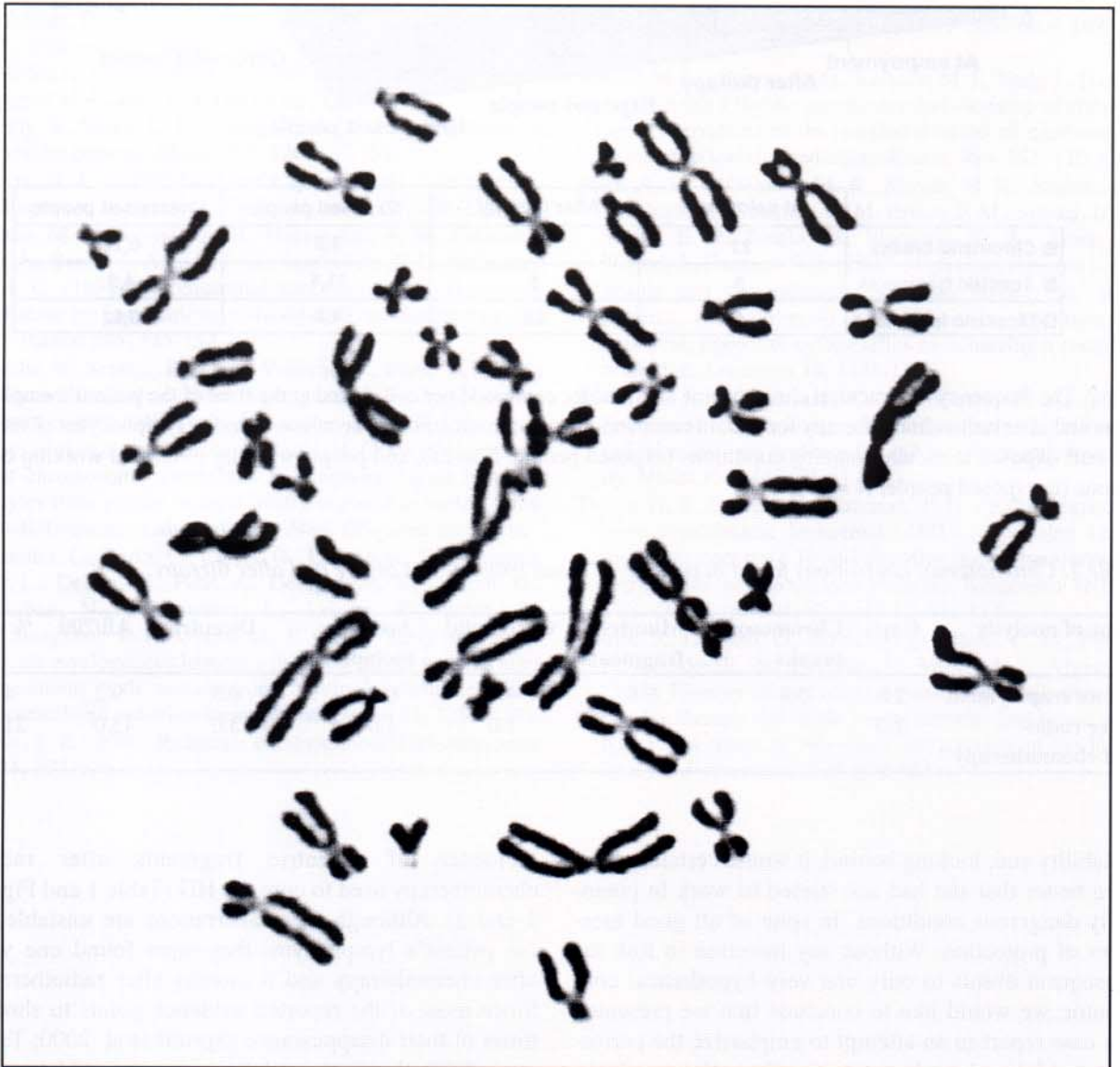


abnormalities in HD are not restricted to pathognomonic Hodgkin/Reed-Sternberg cells, but also to several other cell types (Jansen et al., 1998).

The finding of high incidence of chromosomal instability in our case report after therapy is therefore in agreement with the findings of both authors, those pointing to the presence of chromosomal aberrations induced by HD itself (Deerberg-Wittram et al., 1996; Atkin, 1998), as well as with those reporting about the genotoxic effects of ionizing radiation and chemotherapy for HD (Donaldson et al., 1999; Clemons et al., 2000). The fact that HD appeared in a young medical engineer working in conditions exposed to ionizing radiation during 4 years opened, however, also the question whether the inadequate shielding party was responsible for the development of her disease and finding of such a high frequency of chromosomal aberration after radio-chemotherapy. Regularly made bio-

dosimeter analysis, however, rejected this possibility, showing that her total and annual absorption dose of irradiation was completely inside the permissible values. Similarly, the data of chromosomal analysis, previously obtained on 25 individuals professionally exposed to the same radiation conditions in the same hospital, confirmed that a slightly elevated incidence of chromosomal aberration in this group of medical workers was inside the permissible limits (Lalić et al., 2001). Taken together, this evidence implies that the protection at work was well maintained. There is, however, still a great dilemma related with her initial finding of chromosome aberrations, since analysis showed that at the moment of employment she had greater frequencies of chromatid breaks ( $22.0 \times 10^{-3}$  vs  $0.26 \times 10^{-3}$ ) and dicentric fragments ( $4.0 \times 10^{-3}$  vs  $0.52 \times 10^{-3}$ ) in comparison with healthy, unexposed population (Table 1 and Fig. 2). These findings point to greater genomic



*Fig. 1.* Multiple chromosome aberrations found by conventional metaphase analysis of peripheral blood lymphocytes, stained by Giemsa, one year after chemotherapy and 6 months after radiotherapy for HD.