

Cellular Localization of NGF and NGF Receptors in Aged Human Thymus

(human thymus / involution / NGF / p75^{NTR} / TrkA / immunoreactivity / epithelial cells / microscopy)

T. MARINOVA¹, K. VELIKOVA², S. PHILIPPOV², I. STANKULOV³, G. CHALDAKOV³, L. ALOE⁴

¹Department of Biology and ²Department of General and Clinical Pathology, Medical University, Sofia, Bulgaria

³Division of Cell Biology, Department of Forensic Medicine, Medical University, Varna, Bulgaria

⁴Institute of Neurobiology and Molecular Medicine, CNR, Rome, Italy

Abstract. Recent evidence indicates that some thymic cells of developing and adult laboratory animals express the neurotrophin NGF and its low-affinity p75^{NTR} and high-affinity TrkA receptor. Less is known as to whether the thymus of adult and aged humans express these markers. We hypothesize that the presence and distribution of immunopositive cells for NGF and NGF receptors undergo some alterations during the involution of human thymus. Specimens from normal thymuses of old individuals were obtained from autopsy and surgery cases, and examined immunocytochemically at the light and transmission electron microscopic level. The immunoreactivity of NGF, p75^{NTR}, TrkA and cytokeratin was found in the epithelial thymocyte microenvironment. Our results provide the first ultrastructural evidence for NGF/receptor immunocytochemical localization in human thymus. They suggest a possible immunotrophic/immunoregulatory role of the NGF-p75^{NTR}-TrkA system for T-cell development in human thymus during senile involution.

Neurotrophins are a family of proteins including nerve growth factor (NGF), brain-derived neurotrophic factor, neurotrophin-3 (NT-3) and NT-4/5 (Sofroniew et al., 2001). NGF is the prototypic member of this family (Levi-Montalcini, 1987). Conceived originally as no

more than a growth and survival factor for certain neuronal cells, within the last 50 years increasing information was accumulated showing that NGF also exerts effects on non-neuronal cells, particularly immune cells (reviewed by Aloe et al., 1997a; Aloe and Micera, 1999). The thymus is one recent example of this neuroimmune framework.

The thymus undergoes age-related (physiological, chronic) involution during postnatal development (Von Gaudecker, 1978; Bodey et al., 1997; Turke, 1997; Rodewald, 1998; Goya and Bolognani, 1999). Recent evidence indicates that thymic epithelial cells (TEC), a cellular component that plays an important role in the development and differentiation of T cells, produce NGF and express both low- and high-affinity NGF receptors, p75 neurotrophin receptor (p75^{NTR}) and tyrosine kinase A (TrkA) receptor, respectively (Pescarmona et al., 1993; Aloe et al., 1997b; Parrens et al., 1998; Garcia-Suarez et al., 2000, 2001; Turrini et al., 2001; Yoon et al., 2003). We hypothesize that the presence and distribution of NGF- and NGF receptor-immunopositive cells undergo some alterations during the thymic involutionary process. As a first step in testing this hypothesis we examined these biomarkers' immunoreactivity (IR) in the thymocyte microenvironment of aged human thymus. Here we report structural and ultrastructural data about the cellular localization of NGF, p75^{NTR} and TrkA in human thymus during its age-related involution.

Material and Methods

Specimens from thymuses of old (aged 70–82 years) (N=9) and from young (aged 12–20 years) (N=4) individuals were obtained from autopsy and surgery cases. The thymuses collected have had no pathological disorders. Four kinds of antibodies (Ab), namely anti-NGF rabbit polyclonal Ab (NGF H-20, sc-548, Santa Cruz Biotechnology, Santa Cruz, CA), anti-p75^{NTR} monoclonal Ab (NGFR p75 ME 20.4, sc-13577, Santa Cruz

Received April 22, 2003. Accepted May 20, 2003.

This work was supported by Grant No. 1/2002 from the Medical University, Sofia, Bulgaria, by the Institute of Neurobiology and Molecular Medicine, CNR, Rome, Italy and by Ricerca Finalizzata No. ICS 120.5/RF00.123.

Corresponding author: Tsvetana Ts. Marinova, Department of Biology, Medical Faculty; 2 Zdrave Street, BG-1431 Sofia, Bulgaria. Fax: (+359 2) 9520345; (+359 2) 9520337; Tel.: (+359 2) 5166502; (+359 2) 9520311; e-mail: tmarin@medfac.acad.bg; tsvetamarin@yahoo.com.

Abbreviations: IR – immunoreactivity, NGF – nerve growth factor, PBS – phosphate-buffered saline, p75^{NTR} – p75 neurotrophin receptor, TEC – thymic epithelial cell, TEM – transmission electron microscopy, TrkA – receptor tyrosine kinase A.

Biotechnology), anti-TrkA monoclonal Ab (p-TrkA E-6, sc-8058, Santa Cruz Biotechnology) and anti-Pan-cytokeratin monoclonal Ab (C 1801, Sigma Chemical Co., Deisenhofen, Germany) were used. The IR of NGF, p75^{NTR}, TrkA and cytokeratin was studied. Indirect immunoperoxidase staining, immunogold transmission electron microscopy (TEM) and immunogold-silver staining procedure were applied.

Immunohistochemical study. The indirect immunoperoxidase method was performed according to the protocols previously described (Aloe et al., 1997b, Marinova et al., 2001). Serial cryostat sections from fresh frozen thymuses were used. Anti-NGF Ab, anti-p75^{NTR} Ab and Anti-TrkA Ab were tested in dilution 1 : 200 (incubation time 30 min at room temperature or overnight at 4°C). After three washes in PBS, sections were incubated for 2 h in the ABC staining system (Santa Cruz Biotechnology). The ABC kits (mouse ABC Staining System, sc-2017 for p75^{NTR} IR and TrkA IR, and rabbit ABC Staining System, sc-2018 for NGF IR) were used in the following step of the immunostaining according to the manufacturer's instructions. To achieve a better identification of NGF IR and NGF receptor IR cells, immunostaining on adjacent sections with anti-Pan-cytokeratin Ab (Sigma Chemical Co.) was performed. Formalin-fixed, paraffin-embedded tissue sections were also observed. Some sections were counterstained by Mayer's haemalum. Control experiments (negative and positive controls) were carried out in parallel. Negative controls: staining specificity was assessed by (i) omission of the primary Ab from the reaction sequence; (ii) incubation of sections with pre-immune rabbit or mouse serum, respectively; (iii) replacement of primary or secondary Ab with 1% BSA in PBS. In the positive control experiments isotype-matched control Abs were applied (Sigma Chemical Co.).

Labomicroscope Axioskop 20 (Fb Carl Zeiss Opton, Oberkochen, Germany) was used. **Immunoelectron-microscopic study.** Indirect pre-embedding immunogold TEM and immunogold-silver staining methods were performed according to the standard protocols (Von Gaudecker et al., 1989; Markova and Marinova, 1999; Marinova et al., 2001). Briefly, the more important procedures included: (i) tissue sections cut at 30–50 micrometer thickness with Vibratome were prepared and fixed with 2% paraformaldehyde + 0.1% glu-

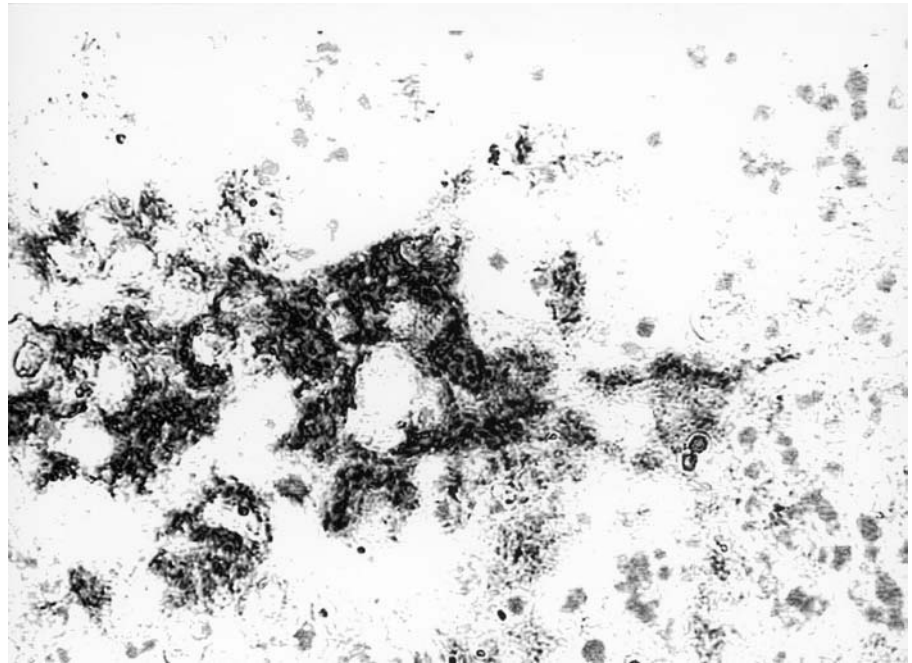


Fig. 1. Young human thymus (17 years old male); NGF-immunopositive TEC; immunoperoxidase staining, Mayer's haemalum counterstaining. Magnification 400x.

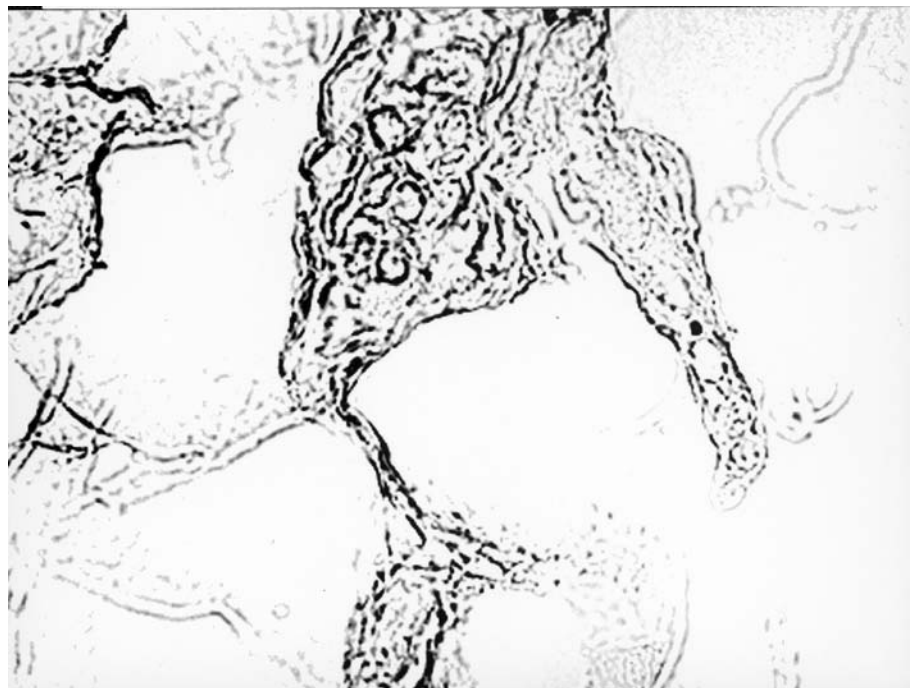


Fig. 2. Aged human thymus (75 years old male); NGF-immunopositive TEC; immunoperoxidase staining. Magnification 1000x.

taraldehyde, as well as unfixed sections that were studied in addition, (ii) samples were incubated with one of the following Abs (anti-NGF Ab, anti-p75 Ab, anti-TrkA Ab) diluted 1 : 200 in PBS-0.1% BSA (1 h at room temperature) and exposed to anti-rabbit or anti-mouse IgG (whole molecule) gold-conjugated (coupled with 5 nm or 10 nm gold particles, Sigma Chemical Co.) diluted 1 : 20 in PBS-0.1% BSA (1 h at room temperature), respectively, and (iii) some sections were silver-enhanced (Von Gaudecker et al., 1989); all sections were afterwards osmicated, dehydrated, embedded and ultrathin-sectioned. The specificity of the immunostaining was assessed by control tests. Electron microscope Hitachi H500 (Tokyo, Japan) was used. Enzyme-linked immunosorbent assay was performed according to Marinova et al. (2001) with some control probes (data not shown).

Results

Immunoperoxidase assay and immunogold TEM demonstrated the presence of NGF IR and also p75^{NTR} and TrkA IR in TEC in all samples examined. Medullary TEC, including those of Hassall's corpuscles and some cortical TEC, displayed strong NGF IR in young individuals (Fig. 1). Structurally, aged thymuses displayed a large mass of adipose tissue containing scattered thymic islands composed of TEC, lymphocytes and reticular connective tissue. Single NGF- (Fig. 2) and NGF receptor-immunopositive TEC (Fig. 3, 4) were observed in senile thymus. The cytoplasm of TEC was moderately NGF-immunopositive. Few TEC showed a strong NGF receptor IR in their long, slender, and whisker-like cytoplasmic processes. Weakly NGF-immunopositive stromal cells displaying morphological features of macrophages were detected in senile thymus. Negative controls were unstained. Immunogold TEM results were in accordance with the immunoperoxidase assay. In

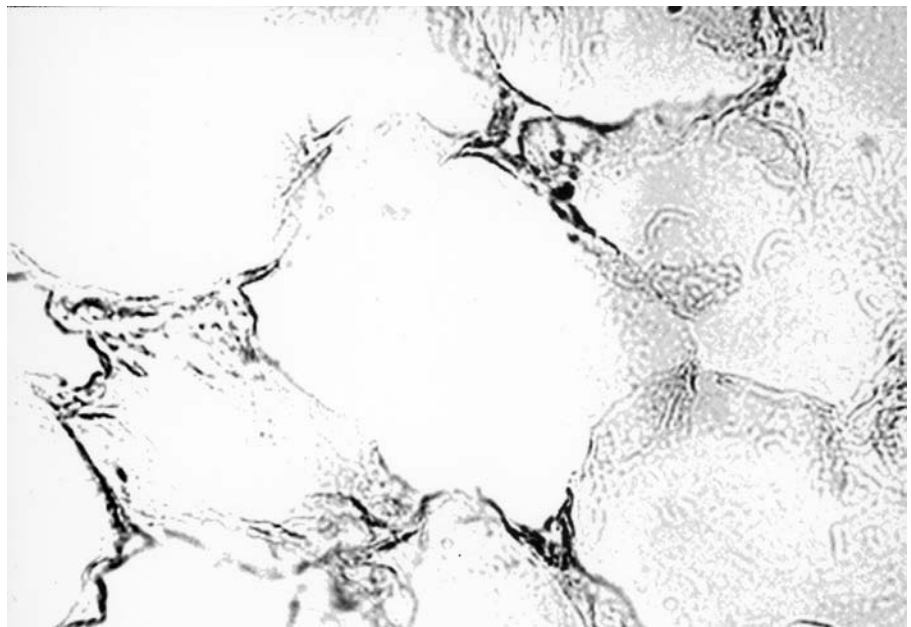


Fig. 3. Aged human thymus (77 years old male); p75^{NTR}-immunopositive TEC; immunoperoxidase staining. Magnification 1000x.

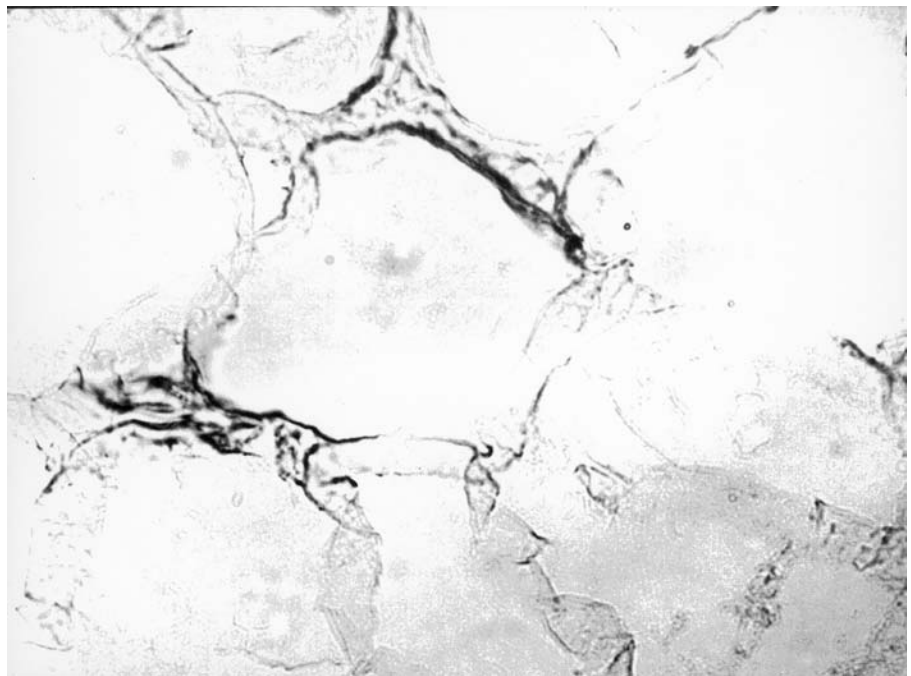


Fig. 4. Aged human thymus (77 years old male); TrkA-immunopositive TEC; immunoperoxidase staining. Magnification 1000x.

aged thymus, the accumulation of NGF-binding gold granules showed low intensity (Fig. 5). NGF-immunopositive TEC processes were in close contact with unstained thymocytes (Fig. 6). Immunonegative TEC were also detected.

Discussion

The thymus is a lymphoepithelial organ that provides the immune system with an optimal microenvironment for the development of T cells (Aloe et al., 1997a,b; Turke, 1997; Marinova et al., 2001; Turrini et al., 2001).

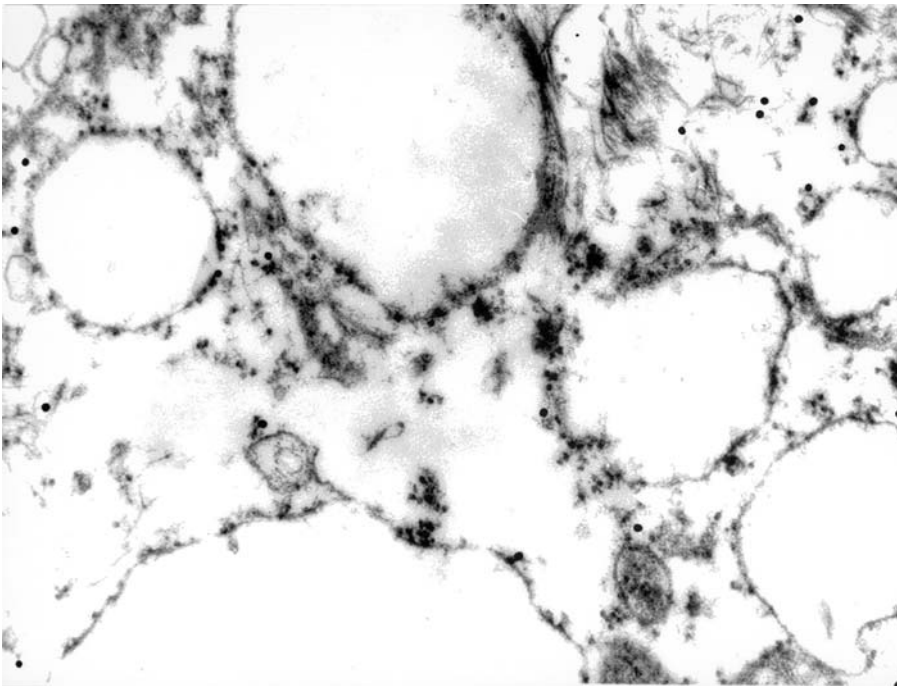


Fig. 5. Aged human thymus (75 years old male); immunogold TEM - localization of NGF-gold granule complexes in TEC. Magnification 32 000x.

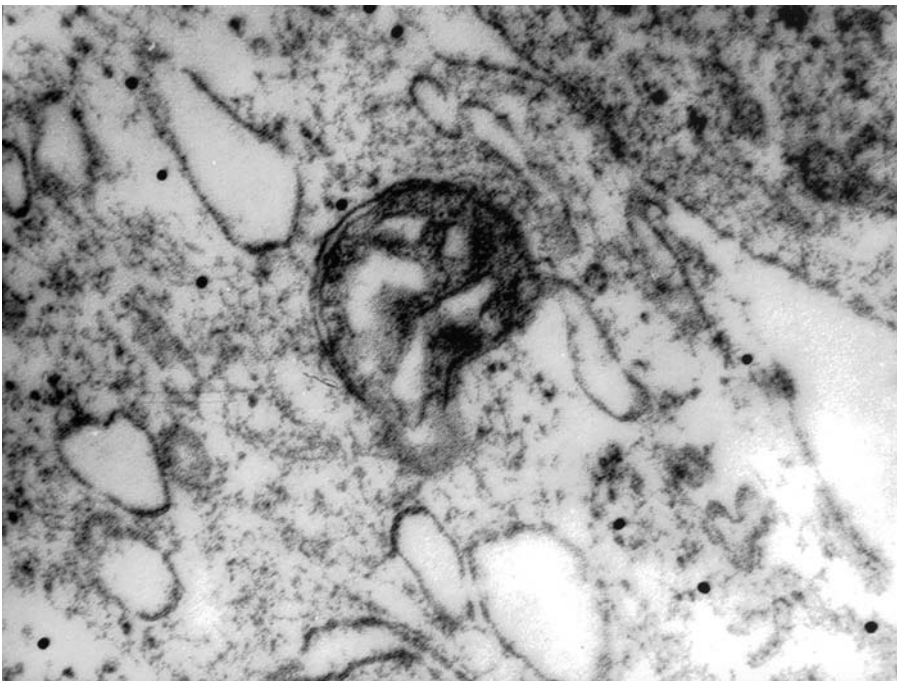


Fig. 6. Aged human thymus (72 years old male); immunogold TEM; NGF-immunopositive TEC in close contact with an immunonegative thymocyte. Magnification 36 000x.

During the ontogenetic development, the thymus undergoes a spontaneous involution in puberty and senility. The mechanisms and the biological mediators implicated in this process are not yet clear. The involution of aging thymus usually involves TEC (Von Gaudecker, 1978; Bodey et al., 1997; Turke, 1997; Rodewald, 1998). Recent studies indicate that a subpopulation of rodent thymic

cells produces a high level of NGF, an endogenously derived neuroimmune mediator, in both prenatal and early postnatal life (Aloe et al., 1997a,b). A significant alteration of NGF levels was found during pregnancy and aging, two events characterized by thymic involution (Aloe et al., 1997b). It is therefore reasonable to hypothesize a functional relationship between thymic functions, NGF and the aging process (Aloe et al., 1997b; Turrini et al., 2001). The role of NGF and NGF receptors in thymus development was investigated until now mainly in animal models (Aloe et al., 1997b; Garcia-Suarez et al., 2000, 2001; Levanti et al., 2001; Yoon et al., 2003). In adult rats and in NGF receptor-deficient mice, both $p75^{\text{NTR}}$ and TrkA were localized by the immunohistochemical technique in a subset of TEC (Garcia-Suarez et al., 2001). Decreased expression of TrkA and $p75^{\text{NTR}}$ in rat thymus was detected during physiological rat thymus involution (Garcia-Suarez et al., 2000).

Some ontogenetic peculiarities of NGF receptor distribution in normal and injured human thymus were observed by immunocytochemistry (Pescarmona et al., 1993; Parrens et al., 1998). NGF receptor (clone ME 20-4) on subcapsular and medullary TEC in foetal early postnatal human thymus was detected by Pescarmona et al. (1993). Likewise, Parrens et al. (1998) reported that TEC of foetal and adult human thymus exhibit TrkA-positive/ $p75^{\text{NTR}}$ -negative phenotype. Interdigitated medullary cells stained for both TrkA and $p75^{\text{NTR}}$ (Parrens et al.,

1998), as well as NGF receptor-immunonegative cortical TEC and macrophages were described (Pescarmona et al., 1993; Parrens et al., 1998).

Overall, our observation supports the hypothesis that NGF and/or NGF receptors might be implicated in thymus functions mediated by TEC (Aloe et al., 1997a,b; Garcia-Suarez et al., 2000, 2001; Turrini et al., 2001).

Whether NGF is involved in some critical immunoneurotrophic action in T-cell responses during thymic involution and/or aging remains to be established. Nevertheless, our observations provide the first ultrastructural immunocytochemical evidence for NGF/receptor expression in human thymus. Most probably, the age-involved thymus is still capable to govern some beneficial microenvironmental events, including NGF/receptor signalling pathways that might be involved in the regulation of T-cell development and plasticity, as increasingly reported for other immune cells (Aloe et al., 1997a; Aloe and Micera, 1999). In conclusion, our present findings suggest a possible immunotrophic/immunoregulatory role for the NGF-p75^{NTR}-TrkA system during the senile involution of human thymus.

References

- Aloe, L., Bracci-Laudiero, L., Bonini, S., Manni, L. (1997a) The expanding role of nerve growth factor: from neurotrophic activity to immunologic diseases. *Allergy* **52**, 883-894.
- Aloe, L., Micera, A., Bracci-Laudiero, L., Vigneti, E., Turrini, P. (1997b) Presence of nerve growth factor in the thymus of prenatal, postnatal and pregnant rats. *Thymus* **24**, 221-231.
- Aloe, L., Micera, A. (1999) Nerve growth factor: basic findings and clinical trials. *Biomed. Rev.* **10**, 3-14.
- Bodey, B., Bodey, B. J. R., Siegel, S. E., Kaiser, H. E. (1997) Involution of the mammalian thymus, one of the leading regulators of aging. *In vivo* **11**, 421-440.
- Garcia-Suarez, O., Germana, A., Hannestad, J., Perez-Perez, M., Esteban, I., Naves, F. J., Vega, J. A. (2000) Changes in the expression of the nerve growth factor receptors TrkA and p75LNGF in the rat thymus with ageing and increased nerve growth factor plasma level. *Cell Tissue Res.* **301**, 225-234.
- Garcia-Suarez, O., Germana, A., Hannestad, J., Ciriaco, E., Silos-Santiago, I., Germana, G., Vega, J. A. (2001) Involvement of the NGF receptors (Trka and p75LNGFR) in the development and maintenance of the thymus. *Ital. J. Anat. Embryol.* **106**, 279-285.
- Goya, R. G., Bolognani, F. (1999) Homeostasis, thymic hormones and aging. *Gerontology* **45**, 174-178.
- Levanti, M. B., Germana, D., Catania, S., Germana, G. P., Gauna-Anasco, L., Vega, J. A., Ciriaco, E. (2001) Neurotrophin receptor-like proteins in the bovine (*Bos taurus*) lymphoid organs, with special reference to thymus and spleen. *Anat. Histol. Embryol.* **30**, 193-198.
- Levi-Montalcini, R. (1987) The nerve growth factor 35 years later. *Science* **237**, 1154-1162.
- Marinova, Ts., Altankova, I., Dimitrova, D., Pomakov, Y. (2001) Presence of HLA-DR immunopositive cells in human fetal thymus. *Arch. Physiol. Biochem.* **109**, 74-79.
- Markova, M. D., Marinova, T. T. (1999) EGF receptor-like determinants on human spermatozoa and their possible cytoskeletal association. *Folia Biol. (Praha)* **45**, 143-145.
- Parrens, M., Labouyrie, E., Groppi, A., Dubus, P., Carles, D., Velly, J.-F., De Mascarel, A., Merlio, J.-Ph. (1998) Expression of NGF receptors in normal and pathological human thymus. *J. Neuroimmunol.* **85**, 11-21.
- Pescarmona, E., Pisacane, A., Pignatelli, E., Baroni, C. D. (1993) Expression of epidermal and nerve growth factor receptors in human thymus and thymomas. *Histopathol.* **23**, 39-44.
- Rodewald, H.-R. (1998) The thymus in the age of retirement. *Nature* **396**, 630-631.
- Sofroniew, M. V., Howe, C. L., Mobley, W. C. (2001) Nerve growth factor signaling, neuroprotection and neural repair. *Annu. Rev. Neurosci.* **24**, 1217-1281.
- Turke, P. W. (1997) Thymic involution. *Immunol. Today* **18**, 407.
- Turrini, P., Zaccaria, M. L., Aloe, L. (2001) Presence and possible functional role of nerve growth factor in the thymus. *Cell. Mol. Biol.* **47**, 55-64.
- Von Gaudecker, B. (1978) Ultrastructure of the age-involved adult human thymus. *Cell Tissue Res.* **186**, 507-525.
- Von Gaudecker, B., Larche, M., Schuurman, H.-J., Ritter, M. A. (1989) Analysis of the fine distribution of thymic epithelial microenvironmental molecules by immuno-electron microscopy. *Thymus* **13**, 187-194.
- Yoon, S., Lee, H.-W., Baek, S.-Y., Kim, B.-S., Kim, J.-B., Lee, S.-A. (2003) Upregulation of TrkA neurotrophin receptor expression in the thymic subcapsular, paraseptal, perivascular, and cortical epithelial cells during thymus regeneration. *Histochem. Cell Biol.* **119**, 55-68.